

See discussions, stats, and author profiles for this publication at: <https://www.researchgate.net/publication/228680983>

# Parasitoses in pheasants (*Phasianus colchicus*) in confined systems

Article in *Veterinarski Arhiv* · January 2006

CITATIONS

8

READS

142

7 authors, including:



**Maria Goldova**

University of Veterinary Medicine and Pharm...

25 PUBLICATIONS 75 CITATIONS

SEE PROFILE



**Valeria Letkova**

University of Veterinary Medicine in Kosice - ...

28 PUBLICATIONS 243 CITATIONS

SEE PROFILE



**Jana Mojzisova**

University of Veterinary Medicine and Pharm...

50 PUBLICATIONS 177 CITATIONS

SEE PROFILE



**Maja Goldova**

University of Veterinary Medicine in Kosice - ...

18 PUBLICATIONS 96 CITATIONS

SEE PROFILE

Some of the authors of this publication are also working on these related projects:



Opportunistic parasitic infections of animals and man [View project](#)

## Parasitoses in pheasants (*Phasianus colchicus*) in confined systems

Mária Goldová\*, Viktor Paluš, Valéria Letková, Alica Kočišová,  
Ján Čurlík, and Janka Mojžišová

Department of Parasitology and Infectious Diseases, University of Veterinary Medicine, Komenského 73, 041  
81 Košice, The Slovak Republic

---

**GOLDOVA, M., V. PALUŠ, V. LETKOVÁ, A. KOČIŠOVÁ, J. ČURLÍK, J. MOJŽISOVÁ: Parasitoses of pheasants (*Phasianus colchicus*) in confined system. Vet. arhiv 76, S83-S89, 2006.**

### ABSTRACT

Samples were obtained from pheasants (*Phasianus colchicus*) bred at the Game Management Centre (GMC) in Rozhanovce to determine the endo- and ectoparasites presented in the birds. Samples were collected monthly. Within the period from 2000 to 2004 1030 samples of pheasant's faeces were examined. Coprological analysis of faeces revealed the presence of *Eimeria* spp. and eggs of nematode (*Capillaria* spp., *Syngamus trachea*, *Heterakis isolonche*, *Ascaridia* spp. and *Trichostrongylus tenuis*). Tissue parasites were examined in 60 pheasants; in 18 samples (30.0 %) microcysts of *Sarcocystis* spp. were found. Two species of mites *Dermanyssus gallinae*, *Ornithonyssus sylvarium* (Acarina, Mesostigmata) and one species of burrowing mite *Knemidocoptes mutans* (Astigmata) were collected. Four species of chewing lice (Phtiraptera: Amblycera, Ischnocera) were described for the first time in the Slovak Republic: *Goniocotes chrysocephalus*, *Goniodes colchici*, *Amyrsidea perdicis*, *Lipeurus maculosus*. Chewing lice in game birds had been previously described in the Czech Republic and Poland; they had not been reported previously in the Slovak Republic.

**Key words:** confined system, pheasant, coccidiosis, helminthoses, ectoparasites, tissue parasites

---

### Introduction

The ring neck pheasant (*Phasianus colchicus*) is a common bird of woodland habitats, adapted to largely cultivated farmland near woodland edges or some bushy areas. It is not a native species of Europe, but it was introduced from Asia in the 15<sup>th</sup> century, probably by the Romans. Wild pheasants have suffered a severe population decline over the last 30 years in Slovakia. This is related to agricultural intensification, particularly increased

---

\* Contact address:

Dr. Mária Goldová, Institute of Parasitology, Diseases of Fish, Bees and Game, Department of Parasitology and Infectious Diseases, University of Veterinary Medicine; Komenského 73, 041 81 Košice, The Slovak Republic; Phone: +421 55 6332213; Fax: +421 55 6331816; E-mail: goldova@uvm.sk.

pesticide use, which reduces insect abundance, crucial in the diet of young chicks (LABISKY and LUTZ, 1967). In many areas of the world, confined systems of game birds help to increase the wild pheasant population. In the special breeding systems for game birds, high concentration of birds together with infectious, mycotic and parasitic agents can cause disease leading to high losses. In the Czech Republic KOTRLÁ et al. (1984) found an 82.5% prevalence of endoparasites in pheasant farms. The most pathogenic species are roundworms (*Syngamus trachea*, *Capillaria* spp., *Heterakis isolonche*, *Ascaridia* spp.) and coccidia (*Eimeria* spp.), which are common in wild and reared game birds and may reduce breeding success (GOLDOVÁ et al., 1993).

Internal parasites can be kept to a minimum by an accurate knowledge of their biological cycles, ways of transmission, and the survival of infective stages of parasites, which can help to prevent the outbreaks of the diseases. Parasites, which have an indirect life cycle, are mainly of importance in range birds and are responsible for severe losses. The purpose of the present study was to determine the most frequent endoparasites with emphasis on the special conditions in intensive cage-breeding systems where different intermediate or paratenic hosts are in high numbers.

Heteroxenous coccidian parasites from the genus *Sarcocystis* in intermediate hosts – birds – can cause fatal disease, when the parasite undergoes schizogony in the capillary endothelium of the lungs and heart during the early stages of the infection (7–14 days post infection). Later stages of infection in intermediate hosts is characterised by formation of muscle cysts (DAME et al., 1995). Susceptibility for the intermediate hosts is less strict, as illustrated by *Sarcocystis falcatula*, for which cowbird (*Molothus ater*) and grackles (*Quiscalus quiscula*) are typical intermediate hosts, however, it also infects finches (Fringilidae), chickens, pigeons, pheasants and psittacine birds (DUBEY et al., 1999). *Sarcocystis falcatula* has not been described in Europe.

The mites (Acarina: Mesostigmata) are widespread from the north to southern parts of Europe. In the collection from pheasants the following were involved: *Dermanyssus gallinae* and *Ornithonyssus sylviarum*. They are common blood-feeding parasites of birds. Parasitism of these mites is demonstrated through disturbance of domesticated and free living birds, irritation, anaemia, transfer of diseases, reduced laying ability, and sometimes - even death. *Dermanyssus gallinae* stay on the host only during the night when they feed for a short (1–2 hours) blood meal; in the day time they are hidden somewhere in the bird's nest, wall cracks where they digest blood and multiply. Although this is a parasite of domestic and wild birds, it can also exist on over 20 mammal types including humans. The burrowing activity of the mite *Knemidocoptes mutans*, which attack epidermis of the feet and legs, causes displacement and inflammation with exudates that hardens, legs become thickened, deformed, and are called as “scaly leg”.

Chewing lice (Phtiraptera: Amblycera, Ischnocera) are mostly an irritant to their hosts. Bird's lice are active, wingless insects, typically 2–3 mm in length. They require the body heat of their hosts in order to survive and therefore spend their entire life cycle on their hosts. Pheasants scratch their head and body, which is likely to relieve the discomfort caused by the action of the lice (WALL and SHEARER, 2001).

### Materials and methods

This study began in 2000 to detect the prevalence of pheasant parasites at the Game Management Centre (GMC) in Rozhanovce, Slovak Republic. Within a 5-year period (2000–2004) 1030 faecal samples of pheasants were examined. Faecal samples from pheasants of different age categories were collected from cages and aviaries of the GMC. Samples were collected monthly. All faecal samples were examined by a qualitative flotation method and the McMaster quantitative method according to MANUAL OF VETERINARY LABORATORY METHODS (1989).

A total of 60 pheasants were examined for tissue parasites by the digestion method. Samples were taken from the breast muscles and heart, subjected to routine tissue digestive method processing (40 ml buffer solution – pH 7.38 and 25 mg trypsin).

For collection of ectoparasites from living birds the fumigation-chamber method was used (CLAYTON and DROWN, 2001). Ectoparasites were fixed in 96 % ethanol and embedded in Canada balsam.

### Results

Of 1030 pheasant faecal samples, 497 were positive (prevalence 48.2%) for internal parasites, only nematodes were found.

Coprological analysis of faeces revealed the presence of *Eimeria* spp. In pheasant chicks up to 2-weeks old the prevalence of coccidiosis was 64%, in 2–8-week-old chicks it was 73%. Five species of nematode eggs were found in pheasants: *Capillaria* spp. 38.4%, *Syngamus trachea* 45.8%, *Heterakis isolonche* 31.7%, *Ascaridia* spp. 10.5% and *Trichostrongylus tenuis* 2.1% (Fig. 1).

Tissue parasites were examined in 60 pheasants; in 18 samples (30%) microcysts of *Sarcocystis* spp. were found (Fig. 2).

Two species of mites (Acarina: Mesostigmata) *Dermanyssus gallinae*, *Ornithonyssus sylvarium* and one species of burrowing mite *Knemidocoptes mutans* (Astigmata) were collected. Four species of chewing lice (Phtiraptera: Amblycera, Ischnocera) were described for the first time in Slovakia: *Gonicotes chrysocephalus*, *Goniodes colchici*, *Amyrsidea perdicis*, *Lipeurus maculosus* (Fig. 3).

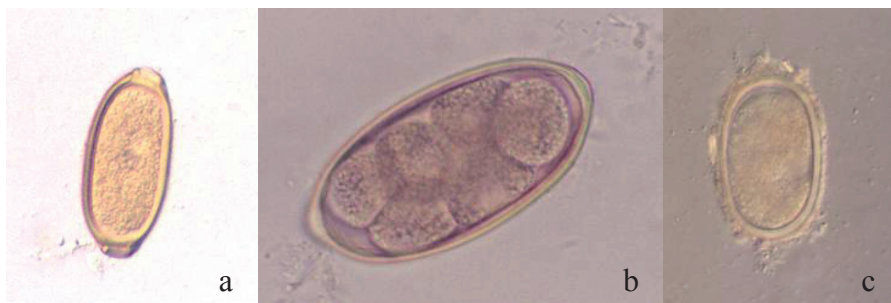

Fig. 1. Endoparasites in pheasant (*Phasianus colchicus*) – flotation method. a) *Capillaria* spp.; b) *Syngamus trachea*; c) *Heterakis isolonchae*

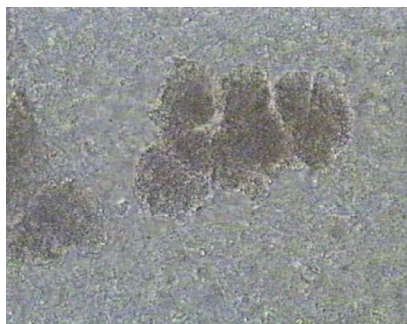

Fig. 2. Microcyst of *Sarcocystis* spp. – digestive method




Fig. 3. Ectoparasites – chewing lice in pheasant (*Phasianus colchicus*). a) *Gonicotes chrysocephalus*; b) *Goniodes colchici*; c) *Lipeurus maculosus*; d) *Amyrsidea perdicis*

## Discussion

Coprological examination during our studies (2000–2004) revealed that the most frequent species infesting these cage–breeding birds are *Eimeria* spp., *Capillaria* spp. and *Syngamus trachea*.

A heavy infection of pheasants with *Syngamus trachea* can produce mortality, but significant losses have not been documented in natural conditions (DAVIDSON and NETTLES, 1988). The rearing of game birds in confinement often results in contamination of the facilities by excretes and subsequent heavy tracheal worm infections. Under such conditions mortality can be much higher. In the GMC, gapeworms are a permanent danger to successful breeding.

Capillariid eggs were very frequent findings. The burrowing activity of *Capillaria* in the mucosa caused necrotic lesions. If the necrosis is severe enough, subsequent complications like diarrhoea, anorexia and cachexia, may develop. In our findings *Capillaria contorta* from the oesophagus and crop was confirmed. Sanitary measures are necessary as treatment, because *Capillaria* (*C. contorta* and *C. caudinflata*) eggs are very durable and have an indirect life cycle. The survival of infective stages is in the intermediate hosts – the earthworm (*Eisenia foetida*, *Allolobophora caliginosa*) is an important factor in the epizootology of capillariosis in gallinaceous birds (MORAVEC, 1982).

The incidence of *Heterakis isolonche*, *Ascaridia galli* and *A. compar* was not significant in pheasants; in partridges only *Heterakis isolonche* was found. In the Czech and Slovak Republics 83.6% of pheasants and 11% of partridges on game–bird farms are infected. In the wild 68.5% of game birds are infected (KOTRLÁ et al., 1984).

The incidence of *Trichostrongylus tenuis* in our findings was infrequent as BOCH and SCHNEIDAWIND (1988) noted. *Trichostrongylus tenuis* infections in the Czech and Slovak Republics according to PÁV et al. (1981) are in 2.4% of the pheasant and 6.5% of the partridge population.

In the Czech Republic SYCHRA (2005) found 5 species of chewing lice (Phtiraptera: Amblycera, Ischnocera) in pheasants breeding on farms: *Amrysidea perdicis*, *Goniocotes chrysocephalus*, *Goniodes colchici*, *Lagopoecus colchicus* and *Lipeurus maculosus*, and seven species on chukars. These findings are similar to ours, which also confirmed the presence of middle-European species in the Slovak Republic.

In Europe sarcocystosis in game birds has not been described yet.

## Conclusion

In our study we confirmed the occurrence of endoparasites in pheasants at the Game Management Centre of the University of Veterinary Medicine, which reached maximum intensity of infection in spring and late autumn. The incidence of parasites increases in connection with the concentration of pheasants on farms. The most frequent species infecting the cage-breeding game birds were *Eimeria* spp., *Capillaria* spp., *Syngamus trachea*, *Heterakis isolonche* and *Ascaridia* spp. Tissue parasites – microcysts of *Sarcocystis* spp. were found.

Ectoparasites *Dermanyssus gallinae*, *Ornithonyssus sylvarium* (Acarina: Mesostigmata), burrowing mite *Knemidocoptes mutans* (Astigmata) were collected. Four species of chewing lice (Phthiraptera: Amblycera, Ischnocera) were described in the Slovak Republic for the first time: *Goniocotes chrysocephalus*, *Goniodes colchici*, *Amyrsidea perdicis*, *Lipeurus maculosus*.

## Acknowledgements

This study was supported by a grant VEGA SR No. 1/1363/04. Special thanks for valuable assistance in the identification of chewing lice to Sychra J., PhD, DVM.

## References

- BOCH, J., H. SCHNEIDAWIND (1988): Krankheiten des jagdbaren Wildes. Verlag Paul Parey–Hamburg und Berlin, Deutschland.
- CLAYTON, D. H., D. M. DROWN (2001): Critical evaluation of five methods for quantifying chewing lice (Insecta: Phthiraptera). *J. Parasitol.* 87, 291-300.
- DAME J. B., R. J. MAC KAY, C. A. YOWELL (1995): *Sarcocystis falcatula* from passerine and psittacine birds: Synonymy with *Sarcocystis neurona*, agent of equine protozoal meningitis. *J. Parasitol.* 81, 916-919.
- DAVIDSON, W. R., V. F. NETTLES (1988): Field Manual of Wildlife Diseases in the Southeastern United States. The University of Georgia, Athens, Georgia, USA.
- DUBEY, J. P., L. VENTURINI, C. VENTURINI, W. BASSO, J. UNZAGA (1999): Isolation of *Sarcocystis falcatula* from the South American opossum (*Didelphis albiventris*) from Argentina. *Vet. Par.* 86, 239-244.
- GOLDOVÁ, M., G. CSIZSMÁROVÁ, V. LETKOVÁ, J. KOČIŠ, L. KOŁODZIEYSKI (1993): Duration of endogenous developmental phase of *Eimeria colchici* and *Eimeria duodenalis* in pheasants (*Phasianus colchicus*). (In Slovak). *Veterinárstvi* 43, 286-287.
- KOTRLÁ, B., V. ČERNÝ, A. KOTRLÝ, J. MINÁŘ, B. RYŠAVÝ, Z. ŠEBEK (1984): Wild animals parasitoses. (In Czech). Academia, Praha, Czech Republic.

- LABISKY, R. F., R. W. LUTZ (1967) Response of wild pheasants to solid-block applications of aldrin. *J. Wildl. Manage.* 31, 13-24.
- MANUAL OF VETERINARY LABORATORY METHODS (1989): Ministry of Agriculture, Fisheries and Food. Reference Book 418. Her Majesty's Stationary Office, London, UK.
- MORAVEC, F. (1982): Proposal of a new systematic arrangement of nematodes of the family Capillariidae. *Folia Parasitol.* 29, 119-132.
- PÁV, J., Z. KOŽUŠNÍK, Z. MATOUŠEK, V. VANČURA, D. ZAJÍČEK (1981): Diseases of game animals. (In Czech). Publ. House SZN Prague, Czech Republic.
- SYCHRA, O. (2005): Chewing lice (Phtiraptera: Amblycera, Ischnocera) from chukars (*Alectoris chukar*) from a pheasant farm in Jinacovice (Czech Republic). *Vet. Med. – Czech*, 50, 213-218.
- WALL, R., D. SHEARER (2001): *Veterinary Ectoparasites: Biology, Pathology and Control.* Blackwells Science Ltd, 2<sup>nd</sup> Edition. Oxford University Press, Oxford, UK.

Received: 15 August 2005

Accepted: 4 April 2006

---

**GOLDOVA, M., V. PALUŠ, V. LETKOVÁ, A. KOČIŠOVÁ, J. ČURLÍK, J. MOJŽIŠOVÁ: Parazitose fazana (*Phasianus colchicus*) u kontroliranom uzgoju. *Vet. arhiv* 76, S83-S89, 2006.**

**SAŽETAK**

Uzorci za određivanje vanjskih i unutarnjih parazita fazana (*Phasianus colchicus*) prikupljeni su na Uzgojnom centru za divljač "Rozhanovce", Slovačka. U razdoblju od 2000. do 2004. godine, jednom mjesečno, prikupljeni su i pregledavani uzorci izmeta fazana. Koprološkom pretragom utvrđena je prisutnost kokcidija *Eimeria* spp. te jajašaca oblića *Capillaria* spp., *Syngamus tracheae*, *Heterakis isolonche*, *Ascaridia* spp. i *Trichostrongylus tenuis*. Također su pregledani uzorci tkiva 60 odstrijeljenih fazana pri čemu su mikrocieste *Sarcocystis* spp. nađene u 18 uzoraka (30,0 %). Osim navedenoga utvrđena je prisutnost grinja *Dermanyssus gallinae* i *Ornithonyssus sylvarium* (Acarina, Mesostigmata) te šugaraca vrste *Knemidocoptes mutans* (Astigmata). Četiri vrste pauši (Phtiraptera: Amblycera, Ischnocera): *Goniocotes chrysocephalus*, *Goniodes colchici*, *Amyrsidea perdicis*, *Lipeurus maculosus*, dokazane su po prvi puta u Slovačkoj. Do sada su pauši pernate divljači dokazivane u Češkoj i Poljskoj, ali ne i u Slovačkoj.

**Ključne riječi:** kontrolirani uzgoj, fazan, kokcidioza, helmintoze, ektoparaziti, tkivni paraziti

---